VOLUME THREE

Evidence of **innovation**

Welland Medical

“SKIN HAS NOT BEEN SORE SINCE USING THE AURA® POUCH.”

Mrs R, UK
Uses Aura® urostomy pouches

Contents

Welland Medical

2020

A VERY SPECIAL YEAR FOR NURSES.

Moira Evans, Clinical Marketing Manager, Welland Medical

2020
INTERNATIONAL YEAR OF THE NURSE AND THE MIDWIFE

> "THE MORE EXPERIENCE WE GAIN, THE MORE PROGRESS WE CAN MAKE."
>
> Florence Nightingale

As we celebrate Florence Nightingale's bicentennial year, designated by the World Health Organisation as the first ever global **Year of the Nurse and Midwife.**

2020 is our time to reflect on these skills, the commitment and expert clinical care they bring, and the impact they make on the lives of so many[1].

Florence Nightingale[2] said "the more experience we gain, the more progress we can make". The common clinical theme throughout this edition is the improvement made to peristomal skin complications following the introduction of medical grade Manuka honey in the stoma flange adhesive.

Together we can review examples of nursing care which have made a positive impact upon patients' quality of life, as we take a trip around the globe to read patient case studies and published articles from Australia, Holland, Italy, New Zealand and the UK.

Through patient scenarios, we are able to follow specialist nurses as they support their patients' journey through peristomal skin complications. Katy Martyn-Skurr reviews the impact of pyoderma gangrenosum, Moira Evans, Pamela White and Lynn Ridley share the impact of dementia upon stoma care, whilst Danielle Barr introduces complex social situations and mental health issues, for Nelleke Van de Vliert and Leila Fatemifar the focus is upon problematic abdominal contours.

The dynamic of change is discussed in Patricia Howson's review of patient education models and the review of patients' clinical needs by Pamela White and Moira Evans.

Peate (2019) stated that: 'The proverb prevention is better than cure means that it is easier to stop something happening in the first place than to have to repair the damage after it has happened'.[3]

This edition recognises stoma therapy nurses in their never-ending quest to enhance the lives of patients with stomas. Florence Nightingale said that we should "live life when you have it. Life is a splendid gift-there is nothing small about it".[4]

Florence Nightingale (1820-1910), photograph ca. 1880

Data held on file.

Welland Medical

OSTOMY CHALLENGES

PERISTOMAL SKIN COMPLICATIONS

Peristomal skin complications are the most common issue following creation of a stoma, Martins et al (2013), and range from mild dermatitis to severe complications such as ulceration or necrosis.

PERISTOMAL PYODERMA GANGRENOSUM (PPG)

Pyoderma gangrenosum (PG) is a debilitating skin disease most often associated with inflammatory bowel disease and is a reportedly rare cause of peristomal ulceration. The lesions of PG rapidly evolve from small, erythematous pustules to deep, painful, pyogenic ulcers within hours to days of onset. Although the behaviour and the appearance of the lesions of peristomal PG are diagnostic, a lack of familiarity with PG often leads to misdiagnosis and inappropriate therapy.[1]

As an uncommon subtype, peristomal pyoderma gangrenosum (PPG), which occurs close to abdominal stomas, comprises about 15% of all cases of PG. The lesions are painful and often interfere with the stoma bag adhering to the abdominal wall, which can cause the contents of the bag to irritate the skin more than usual.[2]

Wallace (2017) suggests that the rarity of pyoderma gangrenosum means that **there is a need for clinicians to share their treatment experiences to act as a guide for future best practice.**[3]

There is no universally accepted guideline for treatment of pyoderma gangrenosum, and no disease-specific therapies have been subjected to controlled clinical trial.[4] Instead, a multidisciplinary approach to treatment is required, and is based on case reports, randomised controlled trials into various drug therapies, and previous clinical experience.

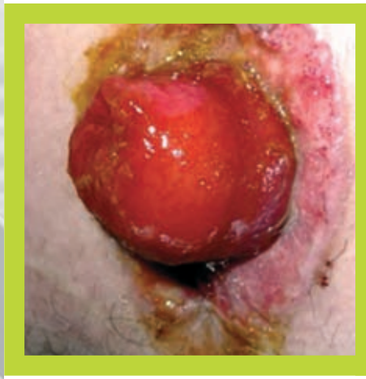

Peristomal pyoderma gangrenosum (PPG) comprises about **15%** of all cases of Pyoderma gangrenosum (PG).[2]

> **"THERE IS A NEED FOR CLINICIANS TO SHARE THEIR TREATMENT EXPERIENCES TO ACT AS A GUIDE FOR FUTURE BEST PRACTICE."**
>
> Wallace A (2017)

STUDY

BALANCING STOMA COMPLEXITIES WITH POUCH CONVEXITY

Moira Evans, Clinical Marketing Manager, Welland Medical Ltd.
Pamela White, Clinical Governance Manager, CliniMed Ltd and SecuriCare (Medical) Ltd.
Lynn Ridley, SecuriCare Nurse Manager (North), SecuriCare (Medical) Ltd.

A review of one patient's journey through peristomal skin complication management.

AIM

To present a patient scenario to demonstrate the positive impacts upon peristomal skin integrity, following the introduction of medical grade Manuka honey within the convex flange adhesive.

OUR PATIENT

An 82-year-old lady with dementia, who was cared for in her own home by her family, this included her daily ileostomy care.

The patient was using a one piece convex pouch.

The family noticed a deterioration in the peristomal skin condition. They had been advised to get in touch with their Stoma Care Nurse (SCN) if they had any concerns relating to the stoma.

The family contacted their SCN following the deterioration of the peristomal skin condition.

WHICH PROBLEM STARTED FIRST?

- Patient attempted to physically remove the pouch during the night
- The impact of dementia upon her stoma awareness
- Reduced adherence of the flange upon the skin
- Discomfort experienced
- Peristomal Moisture Associated Skin Damage: Contact Dermatitis

METHOD

The SCNs utilised SecuriCare Medical Ltd.'s Clinical Stoma Scoring Thermometer tool to acknowledge and manage cumulative risk factors to enable prioritising and proactivity of care input, as the patient's score was ranked as 8, a same day visit was arranged.

NURSE ASSESSMENT 02-NOVEMBER

The SCN's holistic assessment, prompted a change of pouch adhesive to a Manuka honey convex flange to:

1. Improve pouch to skin adhesion
2. Support the improvement of skin integrity
3. Provide comfort to the patient during wear-time

NURSE REVIEW 09-NOVEMBER (7 DAYS)

The review of the change of pouch 7 days later, showed peristomal skin improvement and the same pouch was used until the next planned review date.

TREATMENT CONTINUATION 12-NOVEMBER (10 DAYS)

The holistic nursing care and the change to a Manuka honey adhesive convex pouch had resolved the patient's peristomal skin problems and the use of a convex Manuka honey pouch continued.

*Consent on file to share photos

Poster presented to the ASCN 2019 Conference, ICC Wales.

THE IMPACT OF DEMENTIA UPON HER STOMA AWARENESS

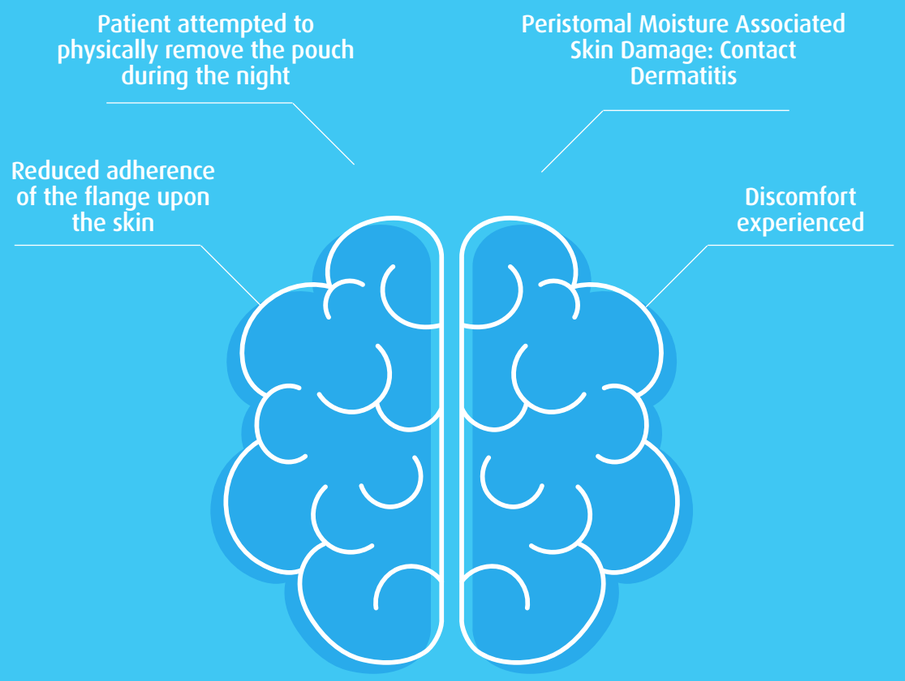

THE PATIENT'S JOURNEY LED TO:

1. The vigilance of the patient's family carers
2. The SCN prompt intervention
3. The change to a convex Manuka honey adhesive flange

All of these have contributed to the resolution of the peristomal moisture associated skin damage experienced by the patient.

CASE STUDY: A CHALLENGING PATIENT

Homelessness and emergency stomal surgery

Dannielle Barr, Registered Nurse, Stomal Therapy Nurse
The Royal Melbourne Hospital, Parkville, VIC 3050

Taken from the Journal of Stomal Therapy Australia – Volume 39 Number 3 September 2019. Printed with the kind permission of the AASTN.

THE PERSON / THE STORY

Mr C presented as an emergency patient via ambulance with severe abdominal pain and haematemesis. Shortly after admission he was taken to theatre and underwent an emergency laparotomy/total colectomy and washout. His large bowel was necrotic from the distal ileum to the proximal rectum with no obvious cause. At this stage the wound was left open (laparostomy) and a topical negative pressure dressing was put in place. The patient was admitted to ICU. The following day he returned to theatre again for a re-look laparotomy/proctectomy and small bowel resection. An end ileostomy was formed at this stage. The patient was critically unwell and it was unknown whether he would survive these procedures. Stomal therapy was contacted on day 2 postoperatively. Surprising everyone, Mr C did recover from his surgery but his stoma proved to be challenging.

SOCIAL, MEDICAL AND SURGICAL HISTORY / DIAGNOSIS

Mr C is an ex-IV drug user and has Hep C. At the time of admission he was officially homeless; although he had been sleeping in emergency housing he had lost his bed when he did not present. He has no next of kin and suffers from PTSD[1] due to childhood abuse from when he spent his youth in a boys' orphanage. He was currently on a high dose anti-depressant and on a methadone programme. He had no relevant surgical history.

The surgical diagnosis was ischaemic bowel of unknown cause. Mr C had no recollection of what event may have triggered the ischaemic bowel. Although he was an ex-IV drug user, he could not recall using in the period prior to admission.

POSTOPERATIVE ASSESSMENT AND DISCHARGE

Mr C's ileostomy was found to be flat, non-spouted, initially sloughy, with healthy tissue becoming visible after using stoma powder for several days. His stoma required a convex appliance and a seal was also used. However, no real issues with this presented during his hospital stay.

Stomal therapy worked closely with social work to emphasise the importance of Mr C returning to emergency housing as we were gravely concerned about him returning to the streets with his new stoma and complicated social history. Thankfully, the social worker was able to secure accommodation back at the place he was previously so he was discharged there.

However, the meals provided had little variation and were not ideal for someone with an ileostomy. In addition, his stoma caused embarrassment to Mr C when it produced noisy flatus. The facility not only had a shared kitchen and living areas but shared bathroom cubicles which left little privacy for changing a stoma appliance.

Mr C became depressed and admitted to being "really, really low". He was struggling with body image associated with the stoma, compounded by ongoing leaks which he attributed to the excess flatus. He also struggled, and continues to struggle, with not knowing why he'd become so unwell in the first place since he has no memory of that time. Cognitively, we thought Mr C may have some short-term memory loss associated with being so critically unwell. In addition, his peristomal skin was erythematous with abrasions and was painful, although the stoma size had decreased.

Figure 1. The Welland Aurum Convex plus belt.

Figure 2. Mr C's stoma.

THE PLAN FOR MR C

It was absolutely critical for us to use a product that would have healing properties. In addition, the appliance would need convexity. It was clear a belt would be beneficial also to 'pop' the stoma out as much as possible due to its flat profile. The product used prior to discharge had a belt, but Mr C found it difficult to manage. The stomal therapy team therefore chose to use the Welland Aurum Convex (Figure 1) with a belt[2]. We needed to be confident that the product would not leak and would heal the sore skin. Another reason we chose this product is that the belt is easy to manage with the velcro that easily slides through the belt hole. As Mr C is often forgetful, it needed to be simple to ensure self-efficacy[3]. We also facilitated a referral to the psychiatric team for ongoing management of his depression.

OUTCOME

Mr C came back to an outpatient appointment a couple of weeks later for review. He loved the Welland Aurum Convex drainable and had experienced no leaks since we had seen him last. He found the pouch easy to empty with the built-in tab. He also loved the ease of the adjustable velcro belt. His skin was healed and was no longer sore as indicated in Figure 2.

Mr C was also now seeing the psychiatrist regularly. Although he still has a long way to go psychologically, having had no leaks for a period of time has made a huge improvement in his confidence, and he is obviously coping much better. For some weeks Mr C chose to have weekly STN OPD appointments which he titrated down as his mental health improved. It was therefore great news to hear this week that Mr C had moved from emergency housing into his own public housing flat where he is living independently.

CASE STUDY: STOMA EDUCATION

For the older person is about keeping it as simple as 1, 2, 3

Rebecca Howson, Stomal Therapy Nurse, Caulfield Hospital, Caulfield VIC 3162

ABSTRACT

Australia's aging population presents unique hurdles when planning, providing care and educating new ostomates, and these variations to care differ greatly depending on the individual.

Whilst there are many predictors to flag potential issues, and well-planned-out pathways for the stoma's physical journey, this article is aimed at highlighting the often overlooked and under-documented complexities encountered as we navigate patients in the transition to home. This is an example of how not all complications and barriers to discharge are due to the stoma, the output, or any medical issue, but rather about the patient's ability to self-manage. The ability to self-manage a stoma is often the defining factor to an aged person's ability to either return to their lives at home or be placed into formal care. This article follows the journey of a non-English speaking background patient transferred from the acute setting to rehabilitation. She was struggling to manage her colostomy appliance which could put her, and her husband with dementia, into residential care – her motivation to prevent this was demonstrated by her readiness to learn. As stomal therapy nurses, it is our responsibility to identify the barriers to self-care, adapt product selection, and implement the most achievable goals. The patient's specific goals and the interventions produced to achieve these were individualised so that she was able to return home to continue to live her life, and not be dictated by her new stoma. This meant that the concept of self-care had to be as simple as 1, 2, 3.

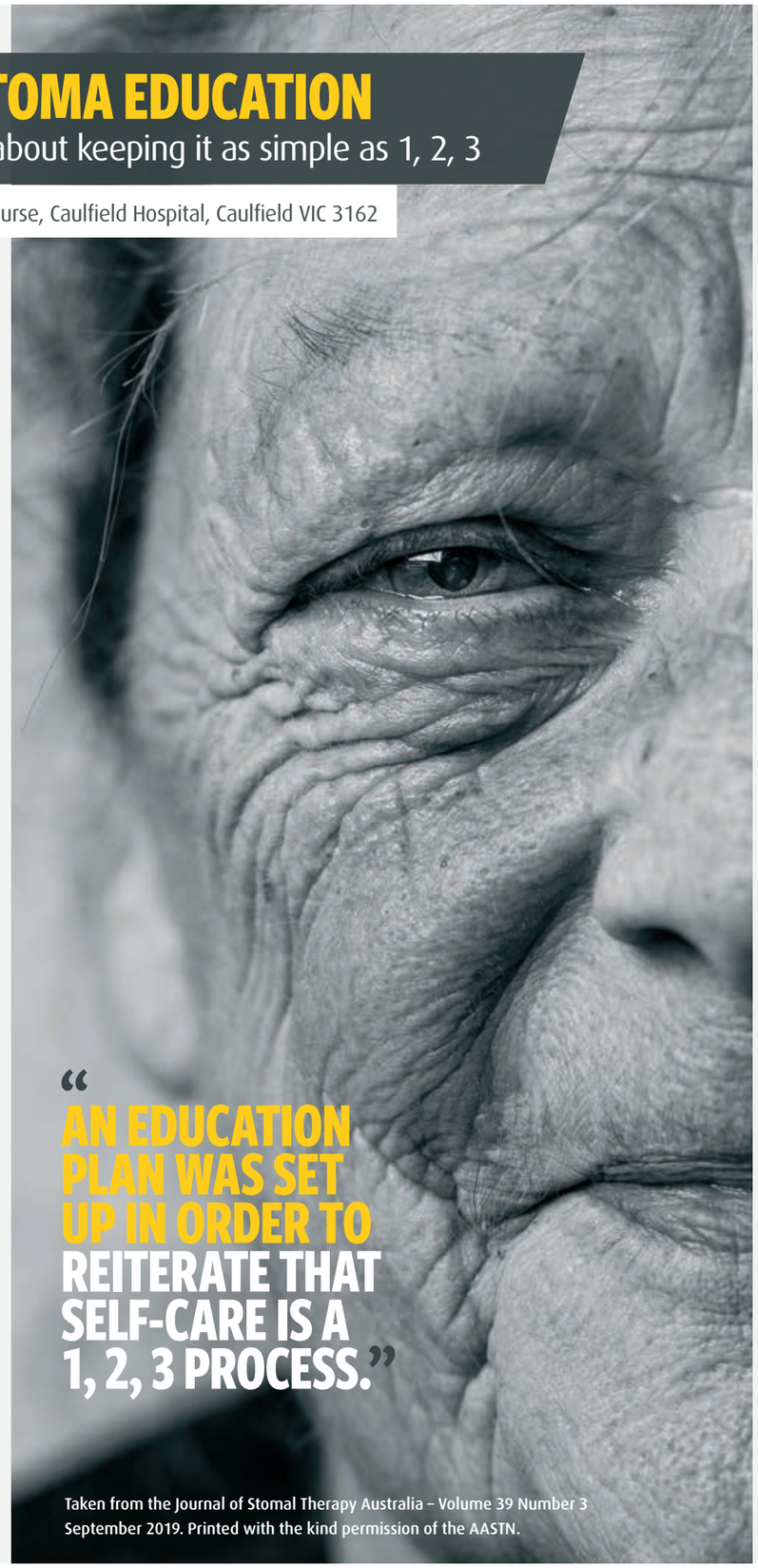

"AN EDUCATION PLAN WAS SET UP IN ORDER TO REITERATE THAT SELF-CARE IS A 1, 2, 3 PROCESS."

Taken from the Journal of Stomal Therapy Australia – Volume 39 Number 3 September 2019. Printed with the kind permission of the AASTN.

BACKGROUND

The aging population presents an array of issues when trying to educate an individual on how to self-manage their new stoma and, with the world's population aging rapidly, this is an area of particular importance.

Between 2015 and 2050, the proportion of the world's older adults is estimated to almost double from about 12% to 22%[1]. In absolute terms, this is an expected increase from 900 million to 2 billion people over the age of 60[1]. In Australia, the proportion of the population aged 65 years and over increased from 12.2% to 15.7% between 1998 and 2018[2]. This group is projected to increase more rapidly over the next decade as further cohorts of baby boomers reach 65 years[2]. Also, over the past 2 decades the number of people aged 85 years and over increased by 125.1% compared with a total population growth of 34.3%[2] over the same period. Typical issues related to aging include loss in dexterity, decreased sensation in extremities, changes to eyesight, decreased problem solving abilities and slower recall. However, the aging brain is still able to learn new skills[3].

In addition, the cultural and linguistic diversity of Australia's resident population has been reshaped over many years by migration. Historically, more people immigrate to than emigrate from, Australia. At 30 June 2017, 29% of the estimated resident population was born overseas (7.1 million persons)[4]. This was an increase from 2016 of 28.6%[3]. In 2007, 10 years earlier, 25.1% of the population was born overseas[4]. These statistics highlight that Australia has not only an aging but also a multicultural population, and while interpreters are invaluable assets they are not always available.

So how do we provide effective education to this cohort of patients? By keeping it simple, as this allows the patients to learn without the need to always have an additional person during all education sessions. Also, by removing unnecessary products and steps in order to simplify the process, the task becomes achievable and increases patients' likely success.

CASE STUDY

Mrs R is an 87-year-old non-English speaking background Greek lady. She lived at home with her husband, who has dementia, and was his primary carer. Since her admission, her husband had been placed into respite care and, if she were unable to achieve independence with her colostomy care, her family had discussed permanent placement for both her and her husband. Whilst Mrs R was able to speak English, an interpreter was utilised during the initial education session to ensure that she was able to fully express the issues with changing her appliance and to have any questions answered. Prior to the stomal therapy nurse review, it was documented that Mrs R was requiring assistance with all aspects related to her colostomy care.

SURGICAL HISTORY

On 20 June 2018 Mrs R underwent an emergency Hartmann's procedure for colonoscopic perforation. This was followed by an extended stay in the acute setting. On 5 July 2018 she was transferred to subacute/rehabilitation for stomal therapy education, assessment and complex discharge planning. At the time the colostomy measured 32 mm, the mucocutaneous junction had healed, but peristomal skin complications were present related to contact with output.

Image is indicative only and not of actual patient.

Figure 1: Mrs R's stoma prior to education. The peristomal skin is unprotected due to a mis-fitting stoma appliance.

Figure 2: Photo care plan for the patient showing the 1, 2, 3 supplies required for bag change.

ISSUES IDENTIFIED

Mrs R explained that she had difficulty cutting the flange to the correct size and also trying to attach the bag to the flange. She was unable to visualise her colostomy without the use of a mirror and said she didn't have 'enough hands' to apply the flange correctly. These issues had caused her to cut the opening for the stoma too large which had led to the circumferential damage (Figure 1). Therefore the main issues were language limitations, a two-piece mechanical coupling, incorrect sizing of product, and difficulties with fine motor skills due to dexterity and sensation.

REHABILITATION PLAN

A number of suggestions were made. Firstly, that Mrs R changes to a one-piece product to simplify the process. Secondly, that she begins to use a pre-cut product and as she was not able to read English well. The Aurum with Manuka Honey was chosen as this came in the appropriate pre-cut size, would aid in healing the damaged peristomal skin, and is easy to apply. Thirdly, that she creates a photo care plan (Figure 2) to refer to when changing her colostomy bag. In addition to this, an education plan was set up in order to reiterate that self-care is a 1, 2, 3 process. This is defined as there being only three things to collect prior to changing.

Figure 3: Photo care plan for the patient showing Step 1: how to remove the bag.

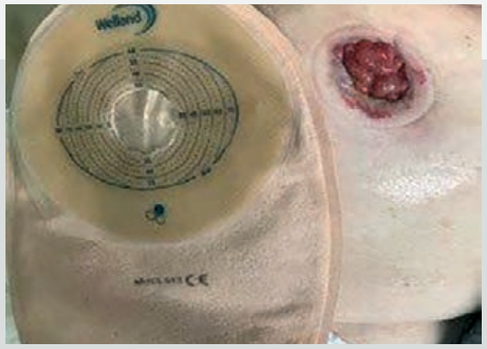

Figure 4: Photo care plan for the patient showing Step 2: cleaning the skin and the stoma.

This is defined as there being only three things to collect prior to changing.

and then that there are three steps to take (Figures 3–6):

Each step was demonstrated by saying 1 as the bag is removed, 2 while cleaning the skin and stoma, and 3 while applying the new bag.

REVIEW

Mrs R reported at the next review that it was much easier to change her appliance and liked having the photo care plan to refer to during appliance changes. Her peristomal skin had improved in the 3 days of using the Aurum with Manuka Honey (Figure 7) and Mrs R also commented that she didn't feel "itchy" around her stoma. She was no longer requiring any assistance from nursing staff and was confident to be discharged home to resume caring for her husband. Mrs R was discharged home with district nurse support.

Figure 5: Photo care plan for the patient showing Step 3: applying the bag.

CONCLUSION

The use of unnecessary products and numerous steps in the process of changing bags creates complicated and confusing tasks for the aged or for those patients with limited English. Simplifying the process allows for all patients to be presented with the same education process and facilitates continuity of care as handover of the process for education is then also simplified. The 1, 2, 3 step education process requires only repetition and practice. STNs provide hands-on bedside education to all patients and, by using this process, can minimise the potential for variation and miscommunication between STNs and bedside nurses.

Note: Consent was obtained to use these images and case study from the patient within the guidelines of the organisation.

Figure 6: Photo care plan for the patient showing Step 3: checking the position of the bag.

Figure 7. Review of the stoma – the peristomal skin showed much improvement.

CASE STUDY

Aurum® 2 urostomy flange in combination with **Aurum® 2** colostomy pouch

A clinical account by Nelleke van de Vliert, Nursing Consultant

Patient

Male, 75, colostomy

Source

Nelleke van de Vliert, Nursing Consultant, Welland Service Team, Welland Nederlands

Problem

Peristomal skin complication

Solution

Aurum®2 urostomy flange in combination with Aurum®2 colostomy pouch and UltraFrame® flange extender

Data held on file.
The views and opinions expressed in this article are those of the source and do not necessarily reflect the views and opinions of Welland Medical.

DIAGNOSIS AND TREATMENT

The Welland Service Team (WST) was approached by a hospital stoma nurse for help. They had a patient with a colostomy who had a severe moist, red and irritated peristomal complication.

The hospital nurses were unable to determine the cause of his skin problem and had already recommended a two piece pouching system, this did not relieve the skin complication and an Aurum 1 piece was given to the patient. Prior to this, the patient used multiple 1 piece flat flange colostomy pouches from several manufacturers.

To clearly identify the problem I visited the patient at his home address.

When I met the patient, he was only able to leave the 1 piece pouch in place for four hours as the flange started to lift away from his skin.

During the home visit I observed that the patient had moist and red skin around his stoma (Figure 1). In addition, the patient had some problems with leakage, probably caused by his very moist skin.

Figure 1. Patient before 22-05-2019.

The next step was to speak to the patient about what one of the causes of the problem could be, namely the moist skin which caused most of the leakage. I decided to use a 2 piece system with an Aurum 2 urostomy flange due to its absorption capacity (Figure 2). I selected a two piece urostomy flange as it has a thicker flange, a deeper hydrocolloid base.

As the skin produced so much moisture, it was decided to initially change the 2 piece system daily, we then extended the pouch weartime to 48 hours during the second week and progressed to a 72 hour weartime from the three week period onwards. In the first week UltraFrame flange extender was used to ensure that the flange remained in place. The outcome was that the urostomy flange appeared to have absorbed most of the moisture from the skin surface.

Figure 2. Aurum 2 urostomy flange in combination with Aurum 2 colostomy pouch.

>>>

HOME VISIT 27-05-2019

Situation after 5 days using an Aurum 2 urostomy flange. Skin is not as moist and the leakage is resolved. Welland Aurum was specifically chosen to enable the skin to heal and recover (Figure 3).

Figure 3. Situation after 5 days using an Aurum 2 urostomy flange.

HOME VISIT 06-06-2019

Skin is still red but dry. The moisture has disappeared. No leakage has occurred since the use of an Aurum 2 urostomy flange (Figure 4). The patient briefly tried an Aurum 1 piece colostomy pouch, but this resulted in moist and red skin again. The decision was made to permanently use an Aurum 2 urostomy flange in combination with an Aurum 2 colostomy pouch and the patient is very happy with this solution.

Figure 4. Home visit 06-06-2019.

OUTCOME AND FOLLOW UP

The patient is comfortable with the use of the Aurum 2 pouch system. Aurum has had a positive healing influence on the moist and red skin (Figure 5). He is able to start his hobbies again, such as gardening.

Figure 5. Home visit 23-08-2019.

CASE STUDY

Providing convexity for a patient with peristomal skin complications using **Aurum® 2** piece convex

A clinical account by Leila Fatemifar, Stoma Therapist Nurse

Patient

A 75-year-old gentleman, who is diabetic and has a terminal end colostomy

Source

Leila Fatemifar, Stoma Therapist Nurse, San Pietro Hospital, Rome, Italy

Problem

Itching and burning across the peristomal area along with continuous detachment of the previous convex pouch

Solution

Aurum® 2 Convex with Manuka honey colostomy pouch

Data held on file.
The views and opinions expressed in this article are those of the source and do not necessarily reflect the views and opinions of Welland Medical.
Printed with the kind permission of Teleflex.

Figure 1.

Figure 2. After two weeks of using Aurum® 2 piece convex.

DIAGNOSIS AND TREATMENT

The gentleman, presented to the San Pietro Hospital in Rome, Italy as an emergency patient. Following diagnosis of a pelvic abscess, the patient underwent emergency surgery resulting in the formation of a terminal colostomy following a Hartmann's procedure. The patient complained of itching and burning across the peristomal area along with continuous detachment of the previous convex pouch.

Upon initial assessment by the Stoma therapist nurse, the stoma was assessed as flush to the abdominal contour with three areas of peristomal ulceration. These can be seen in Figure 1. It is assumed that these have been caused by the previous stoma flange.

The decision to change the stoma flange type from flat to a convex flange was taken and the peristomal area was cleaned and a protective powder and paste applied prior to the flange application.

The Aurum 2 piece was selected as it provided a soft and flexible convexity, whilst the Manuka honey may improve the peristomal lesions.

The peristomal skin integrity improvement can be seen following two applications of the Aurum 2 piece convex pouch (Figure 2). The same skin preparation was undertaken as discussed above.

The three ulcerated areas have significantly improved along with the general peristomal skin area following the introduction of Manuka honey in the flange and the soft convexity.

CONCLUSION

The desired outcome was to enable the stoma effluent to drain into the pouch following the insertion of soft pressure around the stoma via the convex flange, enabling the stoma to be raised rather than continuing to rest so close to the skin.

Welland Medical

CASE STUDY

The use of Manuka honey in the treatment of Pyoderma Gangrenosum revisited

A clinical account by Katy Martin-Skurr, Stomal Therapy Nurse Specialist

Patient

Mrs. D, Female, 38, ulcerated colitis. Underwent an elective total colectomy with end ileostomy

Source

Katy-Martin Skurr, Stomal Therapy Nurse Specialist, Omnigon, New Zealand

Problem

Ulcerated lesions caused by pyoderma gangrenosum (Pg)

Solution

Aurum® Convex with Manuka honey Ileostomy pouch and HyperSeal® Washers with Manuka honey

This case study identifies how, as nurses, we are challenged by our patients in our everyday practice which test our ingenuity and resourcefulness and how we need to constantly refresh our clinical knowledge bank. I hope that through this clinical reflection we can continue to share clinical practice and patient outcomes as Walls (2016) stated this improves our practice and helps to add to our armoury.

Moira Evans, Clinical Marketing Manager, Welland Medical.

Data held on file.
The views and opinions expressed in this article are those of the source and do not necessarily reflect the views and opinions of Welland Medical.
Printed with the kind permission of Omnigon.

PRESENTATION AND HISTORY

Mrs. D has had severe ulcerative colitis which was diagnosed in 2012. Her bowels move up to 10 times a day passing blood and mucous with associated urgency, incontinence and cramping abdominal pain.

Because her condition has been resistant and non-responsive to medical treatment Mrs. D underwent an elective total colectomy with end ileostomy. She recovered well from surgery, discharging home after 4 days in hospital.

Mrs. D managed her stoma well after surgery with no concerns. Her stoma was healthy, 32mm in diameter and well spouted.

She was followed up in the community by both the local district nurses and the stomal therapy nurse.

PARASTOMAL ABSCESS OR PYODERMA GANGRENOSUM?

One month following surgery Mrs. D was seen in the District Nursing clinic. She was troubled by a remaining suture and hypergranulation tissue at the 6 o'clock position (Fig 1). The suture was removed, and the granuloma was treated with silver nitrate.

Over the following month the area became inflamed with what looked like a suture abscess appearing. Mrs. D reported slight discomfort from this area. The area appeared to resolve using stoma powder.

A month later Mrs. D attended surgical clinic with what appeared to be a reformation of the abscess. The Stomal Therapy Nurse (STN) suggested the use of topical betadine. A week later, with little improvement Mrs. D was prescribed antibiotics by her GP. This resulted in some slight improvement.

A week later a new area of concern at 11 o'clock was also noted by the STN and a photograph was taken and sent to her surgeon.

Figure 1. First appearance of painful area at 6 o'clock position inferior to stoma.

>>>

Figure 2. Following incision of what was presumed to be an abscess.

3 months post her initial surgery Mrs. D attended clinic. Her surgeon arranged her admission to hospital for incision and drainage of the apparent parastomal abscess (2.5mm x 0.8mm). The area was excised and opened leaving a larger area of tissue which was painful during pouch changes (Fig 2). At this point I became involved in Mrs. D's care. I was suspicious that as Mrs. D had ulcerative colitis an autoimmune disease we were likely to be dealing with Pyoderma gangrenosum (PG).

PYODERMA GANGRENOSUM (PG)

PG is a rare auto-inflammatory disorder also known as neutrophilic dermatosis. It is associated with other autoimmune disorders including that of inflammatory bowel diseases such as ulcerative colitis and Crohn's disease, rheumatoid arthritis and some haematological conditions. PG may start as a small pustule, red bump or blood blister often starting suddenly after a minor injury. The skin breaks down resulting in extremely painful ulcers with ragged edges and undermining. There may be a bluish coloration to the wound's edges. Surgery is contraindicated as it tends to extend the area and not contribute to healing.

Due to my previous success using the Welland Manuka honey product range for the treatment of PG I commenced using the Aurum® Convex pouch with Welland HyperSeal washer with Manuka honey.

I accompanied Mrs. D a week later to her next clinic appointment. The surgeon agreed with the PG diagnosis and asked for an urgent Dermatology review. The Dermatologist attended clinic and confirmed our suspicions (Figure 3). Application of Locoid® cream, a steroid, was recommended.

We continued to use the Welland Manuka honey products as the PG had shown some improvement from the previous weeks.

Figure 3. Confirmed diagnosis of Pyoderma gangrenosum.

Figure 4. 8 weeks from commencement of treatment.

Figure 5. 10 weeks from commencement of treatment.

The pouch was maintaining a good seal however Mrs. D preferred her previous product. To allow Mrs. D's choice of product we negotiated to continue the use of Manuka honey and the healing of her PG by using a large Welland HyperSeal® washer with Manuka honey underneath the product of her choice. This allowed full coverage of the PG and surrounding peristomal skin.

With the above treatments Mrs. D continued to have a marked improvement in the pain, inflammation and healing so the treatment plan was continued. The healing process took approximately 3 months from PG diagnosis to complete resolution.

The current treatment in use to maintain healthy peristomal skin and prevent the reoccurrence of PG is the smaller Welland HyperSeal washer with Manuka honey (40mm) and intermittent use of Locoid® cream when Mrs. D suspects a flare up (tingling/discomfort and slight erythema).

CONCLUSION

An earlier diagnosis of PG may have prevented the surgery and Mrs. D's prolonged recovery. With the repeated successful use of Welland Manuka honey products for the treatment and prevention of PG reoccurrence, I would now consider and recommend using this product range as a first line choice in patients with autoimmune diseases.

FROM NATURE TO NURTURE

How and why does medical-grade Manuka honey promote skin health? What's the story and the science behind this natural remedy, used for centuries in wound care.

Welland Medical

LIFECYCLE AND PROPERTIES OF MANUKA HONEY

FROM NATURE TO NURTURE

THE PLANT

Leptospermum scoparium

is a shrub or small tree native to New Zealand, that blooms just 2-6 weeks per year. Commonly known as the Manuka or tea tree bush. Tea tree arose because Captain Cook used the leaves to make a 'tea' drink.[1]

THE NECTAR

Manuka
Power of Three

There are three key natural markers in Manuka Honey (Methylgloxal, Leptosperin, and Dihydroxyacetone), which are tested in registered laboratories and the results measure the "Manuka-ness" of the honey.[3]

MGO

Methylglyoxal

A naturally occurring compound with antibacterial and antimicrobial properties that makes Manuka honey so special.

DHA

Dihydroxyacetone

The Manuka flower nectar contains DHA which bees convert (thanks to enzymes in their saliva) to methylglyoxal (MGO).

Leptosperin

A naturally occurring chemical found only in the nectar of Manuka plants. It stays stable over time, which makes testing for Leptosperin in honey a good way of identifying if it contains Manuka, and if it is concentrated enough to be labelled as Manuka honey.

THE GRADE

UNIQUE MANUKA FACTOR®
HONEY ASSOCIATION

Unique Manuka Factor (UMF)

This is the official stamp on honey that has been scientifically tested and graded appropriately. The honey companies that use this gold standards grading system are official licensees of the UMF Honey Association (UMFHA), which has strict criteria and audits its members' packaging and marketing material. Testing for MGO levels is important as they can vary greatly – not all Manuka honey is equal![3]

THE PRODUCT

From Hive to Harvest

Beekeepers gather the honey at the end of the summer season. This harvested honey is tested by The New Zealand Ministry for Primary Industries (MPI) standards and certified using the UMF-approved grading system.

16+ UMF

MEDICAL GRADE MANUKA HONEY

is used in Aurum® ostomy pouches and accessories.

Welland Medical

SKIN FRIENDLY PROPERTIES

MANUKA HONEY

Anti-inflammatory

- Reduces oedema, which reduces pain from pressure on tissues

Provides a moist wound healing environment

- Hygroscopic therefore draws moisture from environment to wound
- Clinical evidence has been published to support the antibacterial properties of Manuka honey to speed up growth of new tissue to heal wounds

Antimicrobial activity

- Low pH: Inhibits bacterial growth
- High sugar content: Reduces water available for bacterial growth
- Methyglyoxal (MGO): non-enzymatic antibacterial compound unique to Manuka honey and is reflected through the MGO content. One way to look at this is that 'traditional' honey and Manuka honey can both exhibit antibacterial properties, but Manuka honey has a unique additional component (MGO) which relies on non-hydrogen peroxide activity
- High viscosity: Forms protective barrier against bacteria

THE pH SCALE

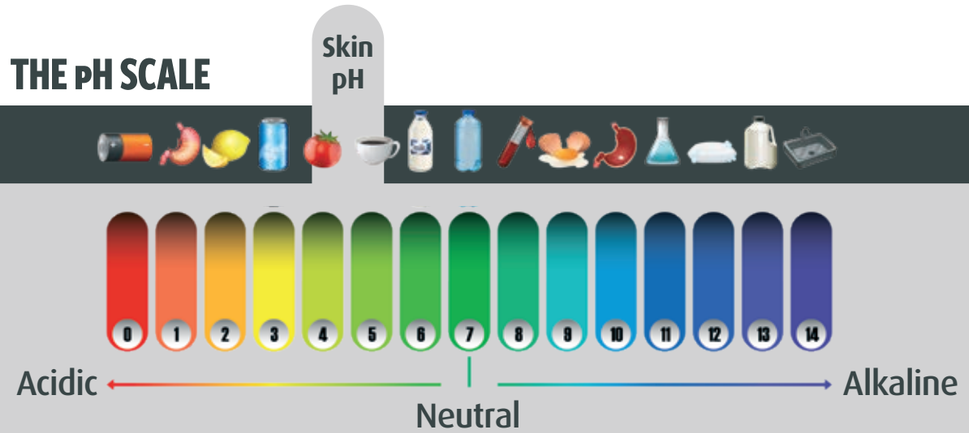

SKIN HEALTH IN STOMA CARE

FROM NATURE TO NURTURE

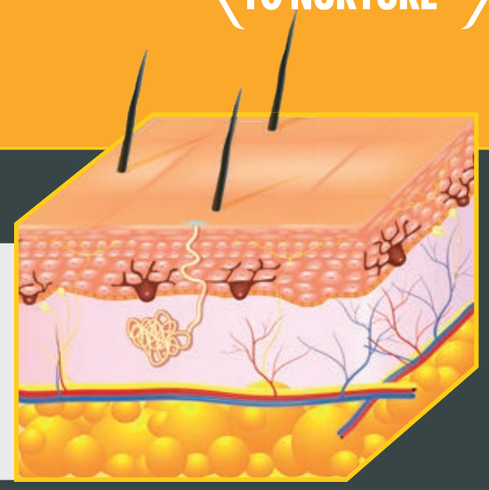

The importance of skin health in stoma care

- The waste output from the stoma can disrupt the normal skin barrier function
- The skin pH is usually between 4.1 - 5.8, but the waste matter from the stoma is alkaline which disrupts this balance and can cause irritation, breakdown and infection of the skin
- Some studies report up to 75 percent of people with an ostomy experience a peristomal skin condition*

Aurum with Manuka Honey

MAORI MANUKA STORY

'Manuka' Meaning

Maori are the indigenous people of Aotearoa New Zealand and have a cultural connection to its taonga (treasure) Manuka. Maori are tangata whenua (people of the land) who are responsible for protecting our taonga for current and future generations.

"Manuka has a whakapapa (genealogy) from a Maori world view. Tane Mahuta – the god of the forests – was responsible for separating his parents Ranginui (sky father) and Papatuanuku (earth mother). After the separation, Papatuanuku was naked and vulnerable so Tane Mahuta covered her in trees. Tane Mahuta married Tawake-toro and they had Manuka. Therefore, from a Maori perspective, Manuka is not just a name on a label but has a whakapapa. This is our Maori story and only we can tell this."

Tane Mahuta
=
Tawake-toro

Manuka

The story of Manuka

"Ranginui (sky father) and PapatĐanuku (earth mother) were locked in an eternal embrace. Their children became frustrated with the cramped conditions and decided to separate their parents – Tane Mahuta (god of the forests) lay on his back and forced his parents apart. He adorned Ranginui with the sun, moon and the stars. He also cloaked his mother with trees. Tane Mahuta had a union with Tawake-toro which gave rise to Manuka. Tane Mahuta also introduced all our native tree species, our native birds and insects. Tane Mahuta also breathed life into the first female giving rise to humankind."

Victor Goldsmith, Ngati Porou Miere Limited Partnership Managing Director

CLINICAL GOVERNANCE FOR OSTOMATES AT RISK OF PERISTOMAL SKIN COMPLICATIONS

Moira Evans, Clinical Marketing Manager, Welland Medical Ltd.
Pamela White, Clinical Governance Manager, CliniMed Ltd and SecuriCare (Medical) Ltd.

ABSTRACT

This clinical study focuses on peristomal skin complications (PSCs). For many patients, the causative factor behind peristomal moisture-associated skin damage was contact dermatitis caused by effluent leakage, resulting in sore and excoriated skin. PSCs are costly to the patient in relation to pain, time and worry and also impact nursing activity levels and healthcare costs. The study identifies the number of patients presenting with PSC, the causative factors and their resolution using medical grade Manuka honey flanges.

Boyles and Hunt (2016) suggested that while:

> **'Many patients will have to deal with problematic skin at some point, it should not be considered the acceptable norm as it can have profound impact on an individual's optimal physical, psychological and social functioning.'**

Improving the quality and safety of healthcare is a system-wide priority. In times when the NHS is under substantial financial pressures to deliver efficiency savings, Getting It Right First Time (GIRFT) has never been more important. According to the website, GIRFT is:

> **'...A national programme, led by frontline clinicians, created to help improve the quality of medical and clinical care within the NHS by identifying and reducing unwarranted variations in service and practice.'**

(NHS Improvement, 2017)

The NHS is expected to deliver efficiencies of 2-3% per year, effectively setting a 10-15% real-terms cost-reduction target for achievement by April 2021, with the aim to make the NHS the safest and most efficient healthcare system in the world (Carter, 2016).

CONSIDERATIONS AND PATIENT SAFETY

Fundamental to any patient intervention or project that has a clinical focus is the role and involvement of clinical governance. The systematic approach to embedding safety, effectiveness and experience into any intervention – be it face to face, written literature or product development – should be a conscious inclusion from the outset. If clinical governance is to truly function effectively, it requires collaboration and people to be in place to advocate and develop it further.

Many may view clinical governance as an abstract concept, however, once it is understood and accepted the advantages often become clear. Those who engage at an early stage benefit from thorough scrutiny and input that may have otherwise been overlooked. Clinical governance itself does not specifically mandate any particular structure for improvement in quality of care, except that the responsibility must exist, and it should be reviewed regularly to ensure that the structure remains robust and fit for purpose in meeting the needs of an organisation.

Risk management and patient safety is pivotal to the ethos of any clinician or clinical interaction and involves conscious consideration of the following:

- Risk to patients; Ensuring the appropriate compliance to statutory regulations aids in minimising and mitigating the overall risk to patients in your care. Ensuring regular review and critical appraisal of current systems makes sure that they remain effective and fit for purpose. Listening, reviewing and feedback that is received in an open and transparent manner.
- Risk to practitioners; Ensuring that clinicians are fully aware of instructions and indications for use of a product they then deem as appropriate in their clinical judgement for the patient. Having access to supportive educational materials for both themselves and the patients is essential in mitigating risk. Validation and safety of any product a practitioner uses is paramount both for them personally and for the safety of their patient. Availability of a product in the UK means that products have undergone testing and processes to ensure it is safe for intended and regulated use. In having such platforms this gives practitioners recourse should any product 'fail' to be able to report via theYellow Card System (MHRA, 2019) – this ensures that clinical responsibility and safety are symbiotic and clearly aligned.

>>>

Patient safety is defined as 'the avoidance of unintended or unexpected harm to people during the provision of healthcare' (NHS Improvement, 2019). Patient safety is an essential element of nursing care that aims to prevent avoidable errors and patient harm. It is a feature of a healthcare system and a set of tested ways for improving care. The Nursing and Midwifery Code (NMC) Code (2018) and the RCN Principles of Nursing Practice (RCN, 2019) promote patient safety. A change in culture is not a necessary precursor for changes in outcomes but it can determine the success and sustainability of patient safety initiatives.

The Care Quality Commission (CQC) has highlighted the need for a change in culture within the NHS to reduce the number of patients who experience avoidable harm. Everyone – including patients – can play a part in making patient safety a top priority. A change in approach is essential if we are to create a culture where learning is shared and where solutions are created proactively to manage risk (CQC, 2018).

Several reporting systems and schemes exist around the UK for reporting adverse incidents and near misses. Adverse incidents involving medical devices must be reported to the Medicines and Healthcare products Regulatory Agency (MHRA) reporting system. The MHRA is an executive agency of the Department of Health and Social Care in the UK that is responsible for ensuring that medicines and medical devices work and are acceptably safe.

A 'CE' mark is a logo that is placed on medical devices to show they conform to the requirements in the regulatory directives. It shows that the device is fit for intended purpose and meets legislation relating to safety. It shows the product can be freely marketed anywhere in the European Union (MHRA, 2016). The Yellow Card System is vital in helping the MHRA monitor the safety of all healthcare products in the UK to ensure they are acceptably safe for patients and those that use them (MHRA, 2019).

CLINICAL CONSIDERATIONS FOR THE OSTOMATE POPULATION

In preparing and adjusting to life with a stoma, patients can often be anxious and will require support in adjusting to and living with a body-altering presence (Lim et al, 2015). Each person with a stoma is an individual and may react differently when faced with similar situations and as such needs to be considered individually to address their needs, support acceptance and encourage rehabilitation. Illness and stressful situations may impact upon a person's ability to engage fully at any given time and articulate problems or concerns (Poland et al, 2017). There are 120,000 people in the UK with a stoma (Boyles and Hunt, 2016) and for each one maintaining an intact peristomal skin throughout their entire pathway and life with a stoma can be challenging.

THE FUNCTION OF THE SKIN

Boyles and Hunt (2016) concisely reported that the skin is:

- Often referred to as the largest organ of the body
- Performs functions vital to the maintenance of homeostasis
- Contains an acid mantle, an invisible covering, with a pH range of 4 to 5.5.

Peristomal skin should have the same appearance as the rest of the abdominal area and should ideally remain intact and free from soreness. However, there are many factors both intrinsic and extrinsic that can damage peristomal skin; the contact of effluent and output from the stoma for prolonged periods can impact greatly on skin integrity.

The incidence of peristomal skin problems is widely reported in literature. However, many instances may be unreported, as often people living with a stoma – especially when well established and adjusted – will self-manage issues and only seek professional help when all other options have been unsuccessful. Studies suggest that a positive quality of life can be achieved when living with a stoma (Hubbard et al, 2017). However, if there is a loss of skin integrity, this can lead to possible issues which will impact on the adhesion of the stoma appliance, giving rise to leakage. This in turn will further impact on the skin integrity and influence the overall quality of that person's life (Erwin-Toth et al, 2012; Maydick-Youngberg, 2017).

Peristomal skin exposed to and in contact with urine and faecal matter can alter the balance of the skin's natural pH or acid mantle. In altering this balance, the skin will have a higher pH, making it more alkaline, which can increase the risks of skin irritation, breakdown and infection.

Another relevant skin function is that of transepidermal water loss (TEWL), which controls the amount of water transferred via the epidermis to the external environment. Gray et al (2011) discussed the impact that 'skin-stripping trauma, infection, eczema and psoriasis' has on the integrity of the skin, which causes an increase in TEWL action.

Peristomal moisture-associated skin damage (MASD) may be caused either by perspiration or the leakage of effluent underneath the flange. Over-hydrated skin, caused by prolonged exposure to moisture, may precipitate inflammation, which together with erosion to the skin occurs initially at the junction between stoma and skin, but can extend for up to 10cm from the stoma (Woodward, 2019).

Grey et al (2011) introduced the concept that MASD requires moisture and the addition of one or more attributable factors, which may include chemical irritants within the moisture source, its pH, mechanical factors such as friction and associated microorganisms.

A study undertaken to review the consequences of PSCs by Meisner et al (2012) concluded that a major focus was needed to minimise the risk, detect PSCs at an early stage and implement treatment to prevent the complications from worsening into a chronic, patient-impacting and expensive complication.

Sica (2018) suggested regularly reviewing whether a patient's pouching system can be improved, as the right appliance makes a vast difference to a patient's health, self-esteem and general wellbeing.

THE AIM OF THE STUDY

Previous retrospective peristomal skin studies have been undertaken by the authors and presented to both World Council of Enterostomal Therapists (WCET) and European Council of Enterostomal Therapists (ECET) conferences. As with many studies, the evidence gathered and presented as a conclusion often raises more questions than answers and requires additional investigation.

The aim of this study was to collate outcomes from a real-life study collating evidence as to how SCNs:

- Assess and review their patients' PSC
- Describe and document the extent of the peristomal skin damage
- Suggest appropriate treatment choices
- Review patients' clinical outcomes

STUDY DESIGN/METHODOLOGY

The SCNs were introduced to the aims of the study and informed that the patient selection criteria focused solely upon the presence of PSC as identified during the physical review of the patient's stoma and discussions with the patient. No additional assessment tools or treatment pathways were introduced by the study.

The study used a questionnaire to capture details of the patient's PSC observed by the SCN, if the patient was deemed suitable to participate by the SCN and the patient gave consent to the SCN. The patient was shown the most suitable Manuka honey pouch (flat, convex or Profile), as clinically determined by the SCN.

The SCN and patient agreed a product evaluation period and also arranged to review the outcomes together. Following the outcome review, the second part of the questionnaire was completed by the SCN.

The end point of the study was to identify whether the introduction of a clinically appropriate pouch following ongoing assessment had a positive outcome in PSC.

The study outcomes focused on:

- Prevalence of leakage episodes
- Prevalence of wear-time adjustments
- Peristomal skin condition
- Patient's view of the pouch experience
- SCN reassessment of PSC

Once completed by the SCN, the questionnaire was forwarded by post to the authors.

CURRENT PRACTICE BASELINE

The study consisted of 58 patients from across the UK, supported by 32 SCNs from 26 independent centres.

The study questionnaire captured a baseline recording of the extent of the PSC issues faced by the 32 SCNs within their nursing caseloads.

- 43% of the SCNs reported that they had over 60% of patients assessed with peristomal skin complications

The most common attributes to PSC from their overall current caseload were:

- Poor patient pouch application technique (98%)
- Presence of uneven abdominal contours (90%)
- Evidence of pouch leakage (86%)
- Evidence of skin stripping (82%)

Figure 1 Peristomal skin to stoma fit; flat/convex and Profile flange types used

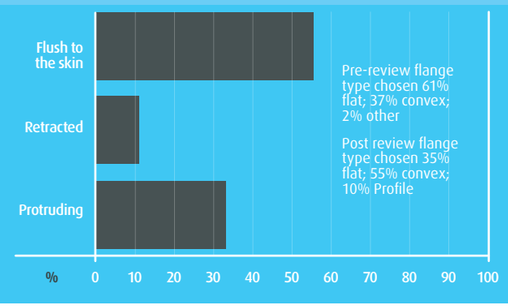

Figure 2 Prevalence of leakage episodes

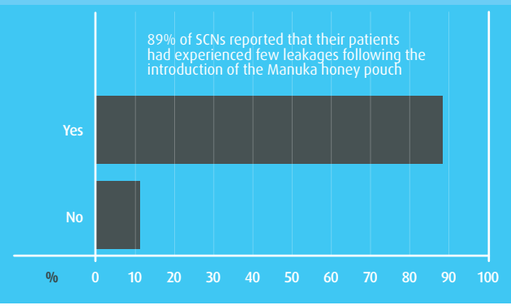

STUDY FINDINGS

An overview of the study findings can be found in Figures 1 to 5. The cohort demographics were:

- Gender: 64% female: male 36%
- Stoma type: colostomy 39%: ileostomy 46%: urostomy 13%: fistula 2%
- Stoma pouch preference: 94% used a one-piece system
- Stoma flange preference: 61% flat: 37% convex: 2% other
- Stoma formation: 46% less than 18 months and 35% within the 2–6 year period
- The appearance of the stoma was reported by the SCNs as 56% flush to the skin, 33% protruding and 11% retracted. Within the study cohort, the following accessory products were routinely used in conjunction with their stoma pouch:
- Silicone medical adhesive remover: 74%
- Barrier product: 46%
- Flange extenders: 30%
- Washer: 24%

Figure 3 Prevalence of wear time adjustments

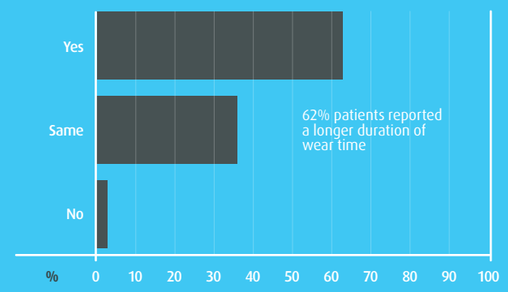

Figure 4 Peristomal skin condition

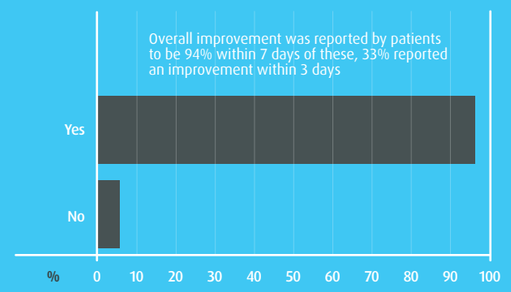

Figure 5 Patient's view of the pouch experience

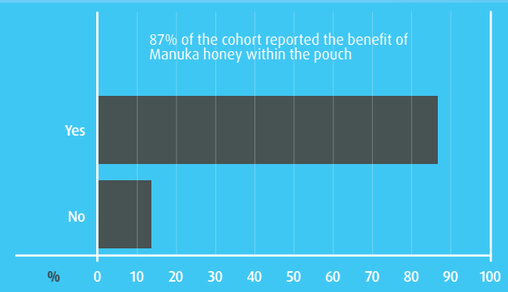

>>>

Figure 6
Peristomal skin complications described by the SCNs

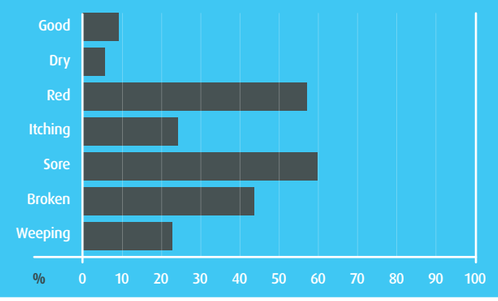

Figure 7
Variations in descriptive terms

The London Procurement Partnership (2018) recommended that prescriptions for accessory products including adhesive removers, skin protectors and adhesive discs/rings should be reviewed to ensure they remain effective.

The study results identify that the largest group of patients presenting with PSC had their stoma formed less than 18 months at the time of the review. Salvadalena (2013) stated:

> **'The most frequent time that the skin becomes sore is between 21 and 40 days after stoma formation'.**

Lindholm et al (2013) stated that:

> **'45% of patients experience problems with their stoma within the first 6 weeks after stoma formation.'**

The peristomal skin complications described by the SCNs are shown in Figure 6.

Boyles (2018) described the complexity of describing PSC and suggests the descriptive approach of word choice like 'sore', 'excoriated', 'red and broken', 'on the left or the right', are highly subjective. She suggested that before descriptive word tools are used in practice, they need to be benchmarked, audited and compared with those of others to improve care standards and outcomes.

One such tool that has been widely used within the specialty of managing the impact of incontinence upon the skin and one of the earliest scoring tools was developed by the National Association of Tissue Viability Nurse Specialists, Scotland (2009). The descriptor groups are listed in Table 1.

Current variations in descriptive terms are apparent across the 26 independent centres who participated within the study, as shown in Figure 7, which are the peristomal skin descriptors recorded by SCNs in this study. The skin descriptors were allocated into sub-groups; the terms and titles used have already been validated by a group of SCNs and consensus gained as part of a previous study undertaken by the authors. Using the sub-groups defined, the SCNs' peristomal skin descriptors were grouped into peristomal skin classifications as shown in Table 2. Further analysis of the SCN's initial PSC assessment, identified that 47% of the cohort had severe peristomal skin damage (Table 3).

Bird (2017) said that the most effective way of reducing the cost of stoma care is to find the right appliance while acknowledging that if the ostomate is having persistent leaks or problems with sore skin something needs to change. Black (2018) further discussed the adverse impact that PSC can have on the patient's quality of life (QoL) citing Agarwal and Erlich (2010) who suggested that inadequate treatment of stoma-related problems may impact QoL while also increasing long-term treatment costs.

PRODUCT SELECTION

The study methodology supported SCNs to independently identify patients with PSC, conduct a peristomal skin assessment and facilitate patient discussion as to the suitability of a change of stoma pouch to a medical-grade Manuka honey flange.

The value of Manuka honey has been described by Woodward (2019) who reported that:

- The antimicrobial properties of Manuka honey have been investigated and it has been found to be bactericidal against a wide range of bacteria that typically colonise chronic wounds, including antibiotic-resistant organisms (Merckoll et al, 2009)
- Honey is non-toxic and there is low risk of bacteria developing resistance (Cooper et al, 2010; Gottrup et al, 2013).

The follow-up review date was determined by the SCN and the patient, the second part of the study evaluation sought confirmation from the SCN and patient when the peristomal skin improvement, if any, was first observed following the introduction of a medical-grade Manuka honey flange.

The SCN's reassessment of the patient's stoma recorded 56% flush to the skin, 33% protruding and 11% retracted, the treatment options chosen for the flange types used in the product evaluation reflect through a reduction of 26% of the flat flange type and patients were changed to a convex (18%) and Profile (8%) flange type.

The importance of the SCN's reassessment of the stoma and type of flange used can be shown through the reduced leakage episodes experienced by the patients during the product evaluation. Of the SCNs, 89% reported that their patients had experienced fewer leakages following the introduction, where clinically appropriate, of a non-flat flange and in all instances a flange containing Manuka honey. This resulted in an increased pouch wear time for 62% of patients.

The overall improvement was reported by patients to be 94% within 7 days of these, 33% reported an improvement within 3 days.

Aminu et al (2000) claimed Manuka honey is a reliable alternative to conventional dressings for managing skin excoriation around stomas (ileostomy and colostomy) by facilitating epithelialisation of the damaged surface.

>>>

Table 1
Classification of skin damage

Group	Inclusion
Healthy skin	Healthy, intact skin. No erythema (redness)
Mild excoriation	Excoriation erythema (redness) of skin only. No broken skin areas present
Moderate excoriation	Erythema (redness) with less than 50% broken skin. Oozing and/or bleeding may be present
Severed excoriation	Erythema (redness) with more than 50% broken skin. Oozing and/or bleeding may be present

Table 2
Stoma care nurses' peristomal skin descriptors

	Good	Dry	Red	Irritated	Sore	Broken	Weeping
Normal							
Mild							
moderate							
Severe							

Table 3
Skin descriptors collated by classification of severity

Normal appearance	6%
Mild	25%
Moderate	22%
Severe	47%

Patients were asked to describe their experience of using an adhesive flange containing medical-grade Manuka honey. The responses were positive and included perceptions and expressions of enhanced comfort, safety and security; feelings of confidence leading to a resumption of daily activity and an improvement in the condition of the peristomal skin.

Qualitative feedback such as this consolidates the importance of ensuring that the patient's experience of and confidence in their pouch system is a positive one.

The SCNs were asked to provide feedback following their patient's experience of the use of the Manuka honey flange (via free text on the study questionnaire). A selection of these comments from the SCNs have been tabulated and are shown in Box 1.

Box 1.

COMMENTS FROM STOMA CARE NURSES

PERISTOMAL SKIN

- The skin improved significantly within a matter of 48 hours
- Felt the pouch was the best for comfort and peristomal skin
- Peristomal skin better
- Improved the peristomal skin condition
- Peristomal skin fully better—no redness and has not required any accessories
- No skin irritation from the flange since changing to the Manuka honey pouch
- The Manuka honey pouch worked well for this patient

PATIENT'S QUALITY OF LIFE

- Patient felt confident
- The patient was so happy with the pouch and wished they had been on these earlier
- This patient had completely lost confidence with his stoma care and is now managing well with his Manuka honey pouch
- Patient really liked the Manuka honey pouch. Improved their quality of life as not worried about pancaking
- The patient now has a positive outlook and accepts the stoma much more and also more confident to self-care
- Patient had been changing previous pouch 4-6 times daily, with this pouch now changing daily
- The patient experienced no leakage and now more confident and happy with the pouch
- The patient is more confident and able to socialise and continue with daily life

POUCH ADHERENCE

- The patient felt the pouch was more secure and gave the patient increased confidence
- Much better for the patient, even when the patient was exercising
- The patient felt that they needed to spend a bit more time warming the pouch and checking that it is secure
- The patient has experienced minimal leaks, is more confident and able to continue with her office work for longer period. The peristomal skin is healthy
- The pouch offered good security and adhesion—the patient liked the option of the belt
- The pouch worked really well for my patient

Figure 8 Case study photos

CASE STUDY

'Anne', an 82-year-old lady with dementia, was cared for in her own home by her family, including daily ileostomy care. The family contacted their SCN following the deterioration of the peristomal skin condition.

At initial assessment the SCN observed contact dermatitis caused by a lack of secure flange adhesion to the skin allowing effluent to seep between the flange and the skin. This was causing discomfort resulting in Anne attempting to remove the pouch during the night. This assessment prompted a change of product to a medical-grade Manuka honey flange with the rationale of improving pouch to skin adhesion, supporting skin integrity and ensuring patient comfort.

The family photographed the skin at each pouch change (Figure 8) and gave informed consent for these to be shared. The holistic nursing care and the change to a medical-grade Manuka honey adhesive flange resolved Anne's skin integrity complications.

>>>

CONCLUSION

Peate (2019) stated that:

> **'The proverb prevention is better than cure means that it is easier to stop something happening in the first place than to have to repair the damage after it has happened, which is very appropriate in health and social care settings.'**

Clinical governance might not be in the forefront of everyone's mind every minute of every day, but it is key to continuous quality improvement, which is important for patient care at all levels. Providers of health and social care services aim to deliver personalised care that is safe, effective, caring, responsive and well-led. Multidisciplinary teams often have to work together, either within or across multiple provider organisations in order to achieve this aim.

All this might seem a little abstract for the day-to-day care of patients, however, specialist nurses working alongside patients with long-term conditions can significantly contribute to addressing the efficiency savings targets required by the NHS. In reducing unwarranted variation in the care delivered and by making clinical decisions relating to products for patients GIRFT has never been more important for both the person with a stoma and the NHS.

Designing and implementing definitive care pathways to manage the challenges presented by people following stoma formation that then can be replicated across an entire stoma care population is challenging due to contextual features of the care settings, geographical localities and localised constraints in which it will be used. Care delivery in the community varies depending on locality with patients seen more or less frequently depending on the assessed clinical need.

In understanding and following up from baseline observations in patients presenting to clinicians with peristomal skin complications, this study shows the importance of re-assessing patients' holistic stoma management in relation to their current peristomal skin condition.

As shown within this study the extent of the problem of peristomal skin complications within their current nursing caseloads was reflected by 43% of the SCNs who reported they had over 60% of patients assessed with peristomal skin complications.

The design of this study enabled detailed patient outcomes to be captured across 26 independent nursing centres, facilitating the review of real-life experiences of patients following the use of a pouching system where the flange contained Manuka honey. The study questionnaire captured the change of treatment pathways implemented by the SCNs as they sought to reduce the level of PSC experienced by their patients.

The change within clinical practice for the study cohort is supported by Kelly O'Flynn's (2016) statement that the assessment and evaluation of the peristomal skin can help nurses decide which is the most appropriate treatment from the wide range of products available.

Results from the independent, multi-centre study supports that through clinical intervention and a reassessment of a patient's stoma, using the most appropriate flange type can improve patient outcomes.

This study brings to the forefront the benefits medical-grade Manuka honey in a flange can provide to both patients and nurses when managing PSC.

Patients and their clinical needs must remain at the very heart of what we do as nurses, a philosophy supported and embedded in the pillars of The Code;

> **'Prioritise people, practice effectively, promote safety and promote professionalism and trust.'**
>
> **(NMC, 2018)**

KEY POINTS

- A study into peristomal skin complications was undertaken. The study integrated clinical governance and the wider patient pathway
- Moisture-associated skin damage is common in ostomates and can contribute to peristomal skin complications
- The independent nurse-led patient study analysed the number of patients presenting with peristomal skin integrity complications, causative factors and means to resolution
- The study results indicated that medical grade Manuka honey might aid in maintaining peristomal skin integrity

CONTINUING PROFESSIONAL DEVELOPMENT (CPD) REFLECTIVE QUESTIONS

- Apply the learning from the information presented to improve outcomes for patients with peristomal skin complications
- Describe any changes and considerations you will make to your daily clinical practice following reading this article
- Consider the portfolios of available stoma pouches and how these may be beneficial in clinical practice
- Review your understanding of evidence relating to the benefits of medical grade Manuka honey

COLOSTOMY UK RUGBY MATCH ULTRAFRAME® INTERVIEW

Many thanks to Oliver, Chris and Kav for sharing their thoughts on UltraFrame®.

So, you are now wearing UltraFrame, how do you feel?

Oliver: Yeah, I can feel it extends the natural part of the pouch

Kav: I always feel like the natural part of the bag you have isn't quite big enough. So, anything to support round the edges helps.

Chris: And they feel invisible and you can't feel it.

Oliver: And the best thing is, you just forget about it. Which is what you want.

Have you worn them before, during physical activity?

All three: I have, yeah.

Chris: To the gym. They bend and move with all your movements and really well shaped.

Kav: You don't really feel like you've got anything on.

How easy were they to apply?

Oliver: Pretty simple. Follow the numbers. As long as you can count to 4, you'll be alright!

What does it mean to you to represent Team Colostomy UK?

Kav: It means an awful lot. It's good to show what is possible. Especially this time round, with the publicity, this one has been immense.

Chris: The reason I wanted to play is just to show everybody who has a stoma you can do all the things you did before.

Oliver: I didn't even play Rugby before I had a stoma. So, I've only just started playing since I've had it. For me its been great to start a new sport and meet lots of people who are in a similar situation.

How did you find the game today?

All three: Great, really good.

Did your stoma bag remain secure throughout the match?

Chris: Absolutely no worries. No problems at all.

How does UltraFrame compare to other flange extenders?

Kav: It's a lot thinner than all the others. Even in everyday activities, you don't feel it. It moulds to your body. It's great.

Oliver: You don't notice it. You want it to be as strong as possible, but not actually notice it's there.

Does it give you the confidence to play without holding back?

Chris: You've seen the film. I don't think anyone was holding back at all!

What was the best part about playing for team Colostomy UK today?

Oliver: I think probably awareness. You can see how many people are here today and the difference that can make. People just knowing about what it is like to have a stoma and it's not a barrier to doing what you want to do.

Chris: If you asked one of the Chorley players who in our team had a stoma, they probably wouldn't be able to tell you. (All three show their stoma bags).

Chris: and I've got two!

REFERENCES

Page 4-5

1. https://www.england.nhs.uk/year-of-the-nurse-and-midwife-2020/ accessed 19.02.2020
2. https://www.azquotes.com/quote/614045
3. Clinical governance for ostomates at risk of peristomal skin complications White P, Evans M (2019) British Journal of Nursing, 2019, Vol 28, No 16
4. https://everydaypower.com/florence-nightingale-quotes/ accessed 13.5.19

Page 6-7

1. Cairns, B.A., Herbst, C.A., Sartor, B.R., Briggaman, R.A. and Koruda, M.J., 1994. Peristomal pyoderma gangrenosum and inflammatory bowel disease. Archives of Surgery, 129(7), pp.769-772.
2. Brooklyn T, Dunnill G and Probert C. Diagnosis and treatment of pyoderma gangrenosum. BMJ 2006;333:181–84.
3. Wallace, A., 2017. Best practice management of peristomal pyoderma gangrenosum. Journal of Community Nursing, 31(1), pp.24-32.
4. Heffernan MP, Milan JA, Smith DI (2007) Adalimumab treatment for pyoderma gangrenosum. Arch Dermatol 143(3):306–8

Page 12-13

1. Shin JH, Hyang SS, Kim EA. Influence of post-traumatic stress disorders on quality of life among patients with ostomy: focused on the mediating effect of resilience. Korean Journal of Adult Nursing 2017 Dec;29(6):657–666.
2. Evans M. The use of Manuka Honey within stoma care to maintain peristomal skin integrity: the ostomates perspective. WCET Journal 2018;38(2):40–40.
3. Simmons KL, Smith JA, Bobb K-A, Liles LL. Adjustment to colostomy: stoma acceptance, stoma care self–efficacy and interpersonal relationships. JAN; Leading Global Research 2007;60(6):627–635.

Page 14-17

1. World Health Organization [Internet]. Mental health of older adults; 2017 [cited 2018 Oct]. Available from: http://www.who.int/en/news-room/fact-sheets/detail/mental-health-of-older-adults
2. Australian Bureau of Statistics [Internet]. Australian demographic statistics; 2018 [cited 2019 Mar]. Available from: https://www.abs.gov.au/
3. Goldstein S. The biology of aging. New England Journal of Medicine 1971;285:1120–1129.
4. Australian Bureau of Statistics [Internet]. Migration Australia 2016–2017; 2018 [cited 2019 Mar]. Available from: https://www.abs.gov.au/ausstats/

Page 26-27

1. Lyon, C. Et al (2000) Parastomal Pyoderma Gangrenosum: Clinical features and management. Jan Acad Derm Jun 42(6)992-1002
2. Cullen, J. Pyoderma Gangrenosum and Related Disorders. BMJ 2006;333:181
3. Simon, A. et al. Medical Honey for Wound Care-Still the Latest Resort? Advanced Access Publication 7 Jan 2008
4. Mandel, M. & Mandal, S. Honey: its Medicinal Property and Antibacterial Activity. Asian Pacific Journal of Topical Biomedicine 2011(1)2:154-160
5. Dunford, C. et al. (2000) Using Honey as a Dressing for Infected Skin Lesions. Nursing Times 96 (14)7-9
6. Walls P, (2016) Faecal fistulae: from despair to hope using stomal therapy 'tricks of the trade' Journal of Stomal Therapy Australia – Volume 36 Number 3 September 2016

Pages 30-31

Source J. T. Salmon, The Native Trees of New Zealand, Reed, 1973

Source: https://www.botany.one/2018/04/what-is-it-that-gives-Manuka-floral-nectar-its-unique-composition/

https://www.hollandandbarrett.com/the-health-hub/food-drink/food/Manuka-honey/Manuka-honey-facts/

Source: www.kanoaManuka.com/leptosperin

Source: haddrells.co.nz/pages/umf

Source: https://www.umf.org.nz/manuka-honey/

www.temarareo.org/TMR-Manuka.html

Page 32-33

Source: Presentation 'Aurum as a First Line Defence in Maintaining Peristomal Skin Health' by Arash Moavenian. PID 5945

Mandal,M. & Madel,S. (2011) Honey: its medicinal property and anti-bacterial activity. Asian Pacific Journal of Tropical Biomedicine. 1(2) 154-160.

Rapp CG, L Richbourg, JM Thorne. Difficulties Experienced by the Ostomate After Hospital Discharge. JWOCN. 2007;34(1):70-79.

Page 34-35

Source: https://www.umf.org.nz/manuka-honey/

Page 36-47

Agarwal S, Erlich A. Stoma dermatitis: prevalent but often overlooked. Dermatitis. 2010;21(3):138-147. https:// doi.org/10.2310/6620.2010.09103

Aminu SR, Hassan AW, Babayo UD. Another use of honey. Tropical Doctor. 2000; 0(4): 250-251

Bird A. Stoma care in a time of financial pressures: can we cut the costs? Br J Nurs; 2017;26(22): S14-S16. https://doi.org/10.12968/bjon.2017.26.22.S14

Black P.The use of flange extenders to support patient care. Br J Nurse. 2016; 25(5): S12. https://doi.org/10.12968/bjon.2016.25.5.S12

Black P. Enhancing the quality of life for stoma patients with appropriate accessory use. Br J Nursing. 2018;27(16): S14. https://doi.org/10.12968/bjon.2018.27.16.S14

Boyles A. Rethinking the language of peristomal skin assessment. Gastrointestinal Nursing. 2018;16(7): 16-18. https://doi.org/10.12968/gasn.2018.16.7.16

Boyles A, Hunt S. Care and management of a stoma: maintaining peristomal skin health. Br J Nurs. 2016;25(17): S14 -21. https://doi.org/10.12968/bjon.2016.25.17.S14

Care Quality Commission. Opening the door to change NHS safety culture and the need for transformation. 2018. https://tinyurl.com/ycjqdxed (accessed 19 July 2019)

Carter P. Operational productivity and performance in English NHS acute hospitals: unwanted variations. An independent report for the Department of Health by Lord Carter of Coles. 2016. https://tinyurl.com/y23kknvm (accessed 19 July 2019)

Cooper R, Jenkins L, Henriques A, Duggan RS, Burton NF. Absence of bacterial resistance to medical-grade manuka honey. Eur J Clin Microbiol Infect Dis. 2010; 29(10):1237–1241. https://doi.org/10.1007/s10096-010-0992-1

Erwin-Toth, P Thompson SJ, Davis JS. Factors Impacting the quality of life of people with an ostomy in North America: Results From the Dialogue. J Wound Ostomy Continence Nurs. 2012;39(4):417-422. https://doi. org/10.1097/WON.0b013e318259c441

Evans SH, Burch J. An overview of stoma care accessory products for protecting peristomal skin. Gastrointestinal Nursing. 2017; 5(7): 25-34. https://doi.org/10.12968/gasn.2017.15.7.25

Gottrup F, Apelqvist J, Bjarnsholt T. EWMA document: antimicrobials and non-healing wounds: evidence, controversies and suggestions. J Wound Care. 2013;22(5 Suppl): S1-89. https://doi.org/10.12968/jowc.2013.22.Sup5.S1 (accessed 19 July 2019)

Gray M, Black JM, Baharestani MM et al. Moisture-associated skin damage: overview and pathophysiology. J Wound Ostomy Continence Nurs. 2011; 38(3): 233–41. https://doi.org/10.1097/WON.0b013e318215f798

Hubbard G,Taylor C, Beeken R et al. Research priorities about stoma-related quality of life from the perspective of people with a stoma: A pilot survey. Health Expect. 2017;20(6): 1421–1427.

Kelly O'Flynn S. Protecting peristomal skin: a guide to conditions and treatments. Gastrointestinal Nursing. 2016;14(7): 14- 19. https://doi. org/10.12968/gasn.2016.14.7.14

Lim SH, Chan SWC, He H-G. Patients' experiences of performing self-care of stomas in the initial postoperative period. Cancer Nurs. 2015;38(3):185– 193. https://doi.org/10.1097/NCC.0000000000000158

Lindholm E, Persson E, Carlsson E et al. Ostomy-related complications after emergent abdominal surgery: a 2-year follow-up study. J Wound Ostomy Continence Nurs. 2013;40(6): 603–10. https://doi.org/10.1097/WON.0b013e3182a9a7d9

London Procurement Partnership. Recommendations for stoma prescribing in London, Medicines Optimisation and Pharmacy Procurement (MOPP) Workstream. London Procurement Partnership; 2018

Maydick-Youngberg D. A descriptive study to explore the effect of peristomal skin complications on quality of life of adults with a permanent ostomy. Ostomy Wound Manage. 2017;63(5): 10-23

Meisner S, Lehur PA, Moran B. Matrins L, Jemec GBE. Peristomal skin complications are common, expensive and difficult to manage: A population based cost modelling study. PLoS One. 2012;7(5):e37813. https://doi.org/10.1371/journal.pone.0037813

Merckoll P1, Jonassen TØ,Vad ME, Jeansson SL, Melby KK. Bacteria, biofilm and honey: a study of the effects of honey on 'planktonic' and biofilm-embedded chronic wound bacteria. Scand J Infect Dis. 2009;41(5):341– 347. https://doi.080/00365540902849383

Medicines and Healthcare products Regulatory Agency. Medical devices: conformity assessment and the CE mark. 2016. https://tinyurl.com/y34g4ojj (accessed 19 July 2019)

Medicines and Healthcare products Regulatory Agency. Yellow card. 2019. https://yellowcard.mhra.gov.uk/ (accessed 19 June 2019)

National Association of Tissue Viability Nurse Specialists (Scotland). Skin excoriation tool for incontinent patients. Quality Improvement Scotland. 2009

NHS Improvement. Getting it right first time (GIRFT) recruits new clinical leads. 2017. https://tinyurl.com/yyrzpvlu) (accessed 19 July 2019)

Nursing and Midwifery Council.The code: professional standards of practice and behaviour for nurses, midwives and nursing associates [Online]. 2018. www.nmc.org.uk/globalassets/sitedocuments/nmc-publications/nmc- code.pdf (aAccessed 10 June 2019)

Peate I Well funded prevention is indeed better than cure British Journal of Nursing. 2019;28(5):275

Poland F, Spalding N, Gregory S, et al. Developing patient education to enhance recovery after colorectal surgery through action research: a qualitative study BMJ Open [online]. 2017. https://bmjopen.bmj.com/ content/7/6/e013498 (accessed 18 July 2019)

Royal College of Nursing. Principles of nursing practice. 2019. https://tinyurl. com/y6zo7uw4 (accessed 25 July 2019)

Salvadalena G.The incidence of stoma and peristomal complications during the first 3 months after ostomy creation. J Wound Ostomy Continence Nurs. 2013;40(4): 400-406. https://doi.org/10.1097/WON.0b013e318295a12b

Sica J. Helping ostomates choose the right appliance for their stoma Gastrointestinal Nursing 2018; 16(7)20-22

White R.The benefits of honey in wound management Nursing Standard 2005;20(10): 57-64

Woodward S. Moisture-associated skin damage: use of a skin protectant containing Manuka honey. British Journal of Nursing. 2019;28(6);329-335

“CREATIVITY IS INTELLIGENCE HAVING FUN.”

Albert Einstein

Welland Medical Ltd., Hydehurst Lane, Crawley, West Sussex RH10 9AS United Kingdom
Tel: +44 (0) 1293 615455 **Fax:** +44 (0) 1293 615411 **Email:** info@wellandmedical.com

www.wellandmedical.com

PID 8654 • 05-2020 • Volume 3